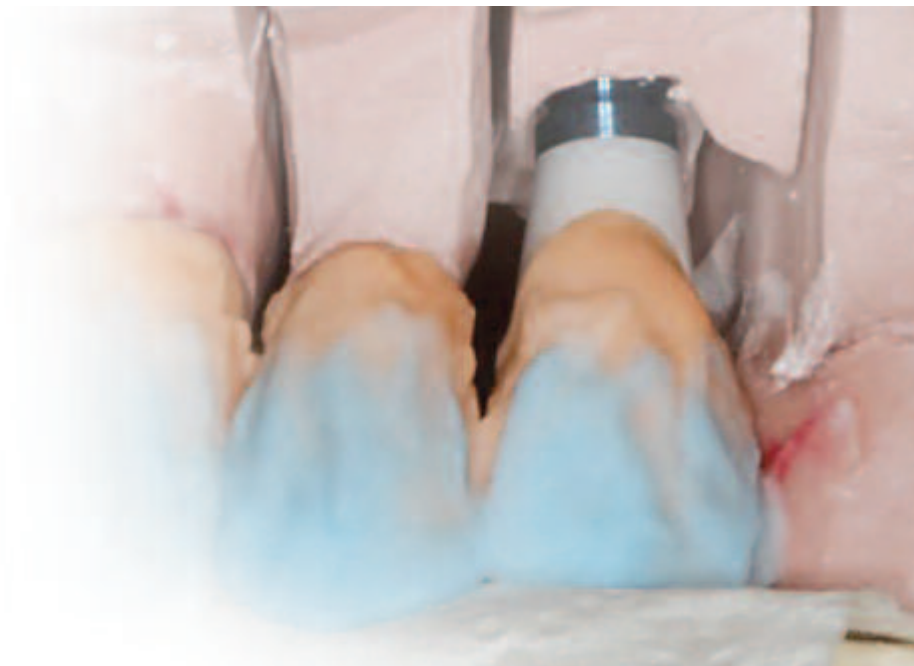



CLINICAL PERSPECTIVES

Inside this issue:

Using digital technologies to address aesthetic challenges in the anterior maxillae



Using digital technologies to address aesthetic challenges in the anterior maxillae

Pär-Olov Östman, DDS, PhD



The application of computer-aided design and computer-aided manufacturing (CAD/CAM) technologies to implant dentistry has had a number of wide-ranging considerations. These include the ability to mill implant abutments, frameworks and ceramic crown copings from ceramic materials. Digital dentistry enables accurate component fit and precise marginal adaptation. The following case presentation illustrates the use of digital dental techniques to replace a fractured anterior tooth and cosmetically enhance the remaining anterior teeth in a 70 year old patient.

Key Words: aesthetics, digital dentistry, zirconia, anterior restoration

Introduction

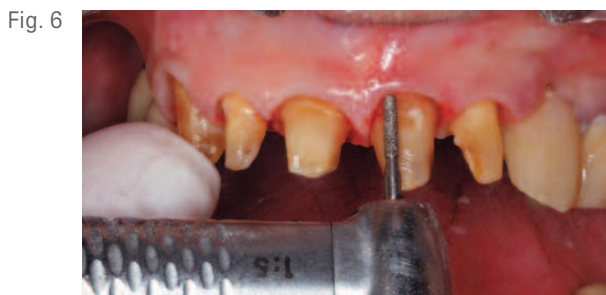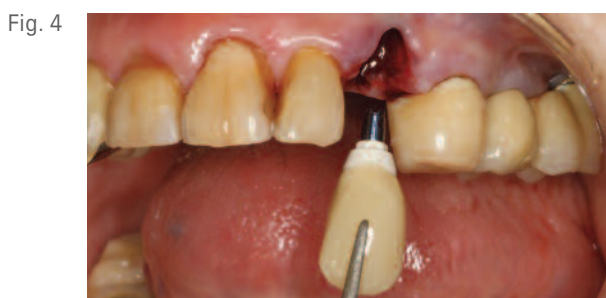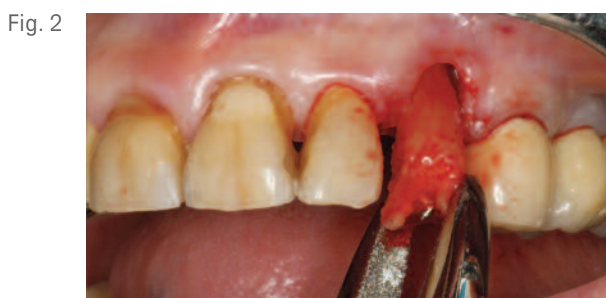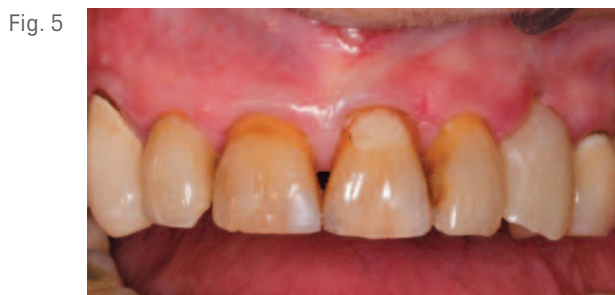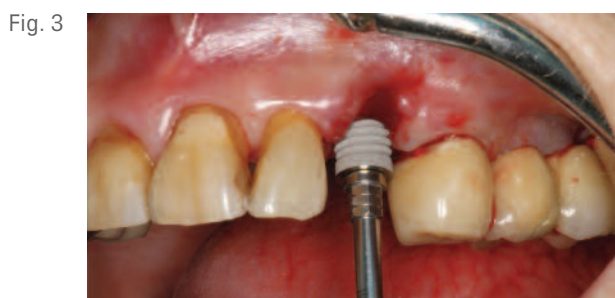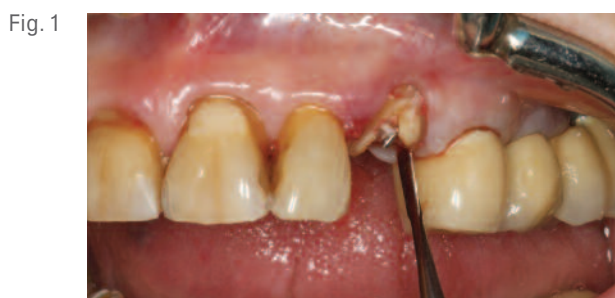Immediate implant loading has become an attractive option for meeting some of the aesthetic and biomechanical challenges associated with using implants to replace single teeth, particularly in the aesthetic zone. Patients desiring improvement of their smiles with fixed restorations and aesthetic enhancements represent a growing segment of the population that can benefit from digital technologies. These technologies enable clinicians and laboratory technicians to fabricate aesthetic restorations with appropriate gingival contours.

Clinical Case Presentation

The following clinical presentation demonstrates the treatment of a 70 year old female patient who

presented for replacement of tooth No. 11 [23], which had fractured due to trauma. She desired a fixed restoration, along with cosmetic enhancement of her unaesthetic, discolored maxillary anterior teeth. Clinical and radiographic examinations confirmed that the patient had adequate bone volume to allow for placement of a dental implant immediately following extraction of the fractured canine.

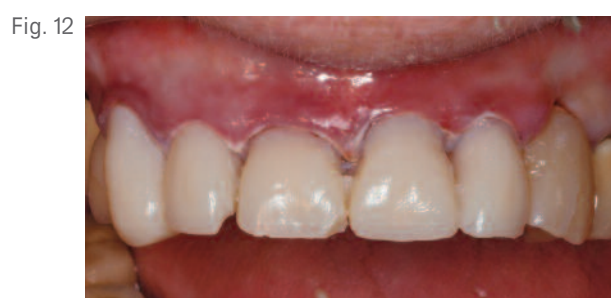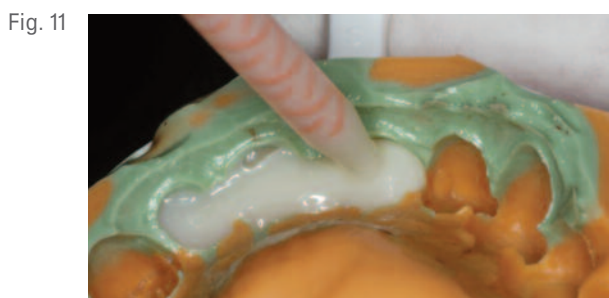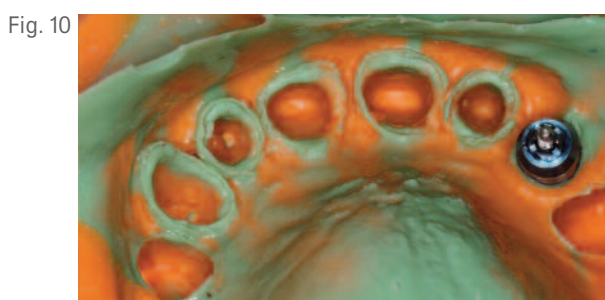
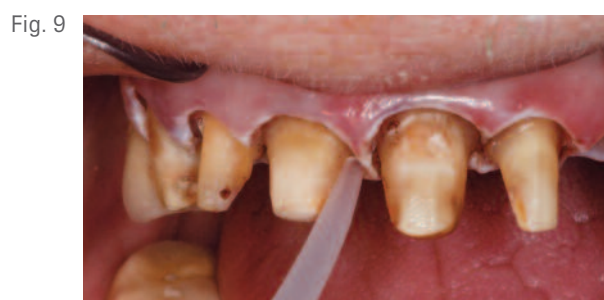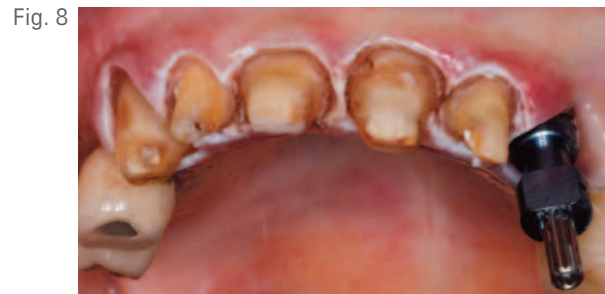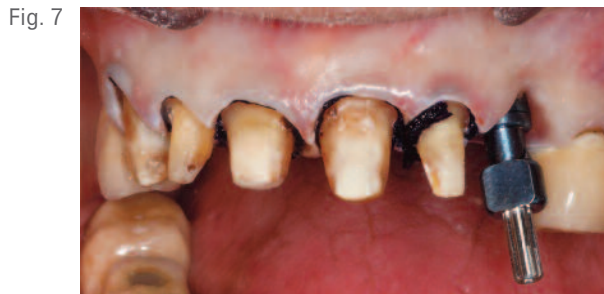The treatment plan called for the implant to be restored with a single-unit, zirconia Lab Designed Abutment (BIOMET **3i**, Palm Beach Gardens, Florida, USA) and an all-ceramic crown fabricated on a BellaTek™ Zirconia Coping (BIOMET **3i**). The natural teeth were to be restored with the



placement of all-ceramic restorations fabricated on BellaTek™ Zirconia Copings for teeth Nos. 6-10 [13-22]. Following removal of the crown, a periosteal elevator was used around the remaining root tip of the fractured tooth (Fig. 1) to protect the integrity of the buccal plate during extraction. The root tip was then carefully extracted with forceps (Fig. 2). After following the recommended drilling sequence, a 5mm diameter x 15mm length Certain® (internal connection) Implant (BIOMET 3i) was placed (Fig. 3) 2mm below the buccal bone margin.

Evaluation of the implant stability with an Osstell ISQ Instrument (Osstell AB, Gothenburg, Sweden) showed the implant stability quotient (ISQ) to be 82, which was deemed sufficient to allow for immediate

provisionalization of the implant. A PreFormance® Post was placed on the implant and secured with a screw tightened to 20Ncm. The screw-access opening was blocked-out with polyvinylsiloxane light-body impression material. A prefabricated crown form was tried in on the prepared abutment. The form was then filled with composite resin, taking care not to overfill the prefabricated crown to avoid contaminating the implant-placement site. After light-curing the composite resin, the block-out material over the abutment screw was removed. The provisional crown was then removed, contoured, polished, and replaced into the internal interface of the implant (Fig. 4). The screw was tightened and the screw-access opening was restored.



The patient returned 12 weeks later (Fig. 5), and an impression was made of the existing anterior teeth, with the implant-supported provisional restoration in place. Teeth numbers 6-10 [13-22] were then prepared with an SS White Disposable Diamond Bur (SS White Burs, Inc., Lakewood, New Jersey, USA) (Fig. 6). A Gingi-Plain® Retraction Cord (Gingi-Pak®, Camarillo, California, USA) was placed in the sulci around the tooth preparations, and a pick-up impression coping was placed into the implant (Fig. 7). After three minutes, the retraction cord was removed, and the prepared teeth were rinsed and dried (Fig. 8). Light-body polyvinylsiloxane impression material (Affinis®, Coltène Whaledent®, Switzerland) was syringed around the tooth preparations and the implant impression coping (Fig. 9). A stock tray with

a hole created in the area of the implant was filled with heavy-body impression material and seated, per the manufacturer's instructions, until set, then removed (Fig. 10). An impression was made of the opposing arch.

To fabricate the provisional restoration, an impression made before preparation of the teeth was filled with self-curing acrylic resin (Fig. 11). This was allowed to set for three minutes. The restoration was trimmed, polished, and secured to the prepared crowns with temporary cement (Fig. 12).

In the dental laboratory, a soft-tissue model was fabricated around the implant analog in the impression made of the implant and tooth preparations (Fig. 13).

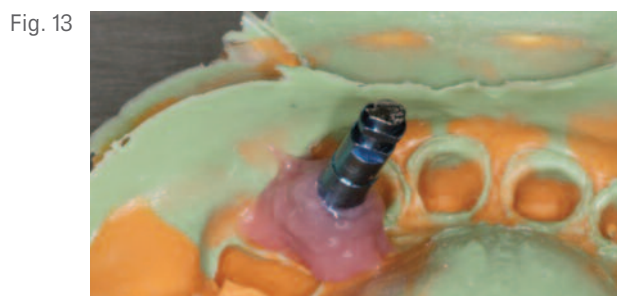

Fig. 13

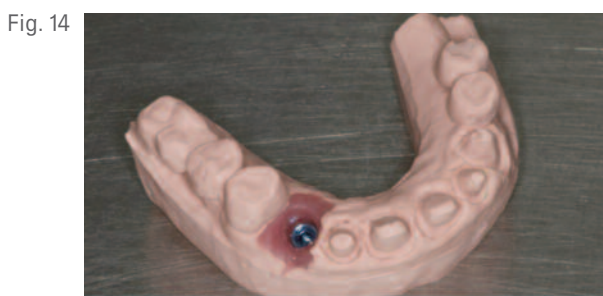

Fig. 14

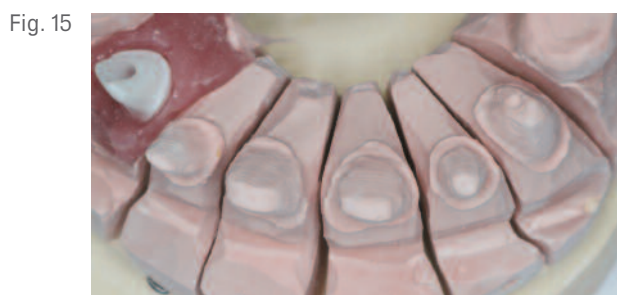

Fig. 15




Fig. 16

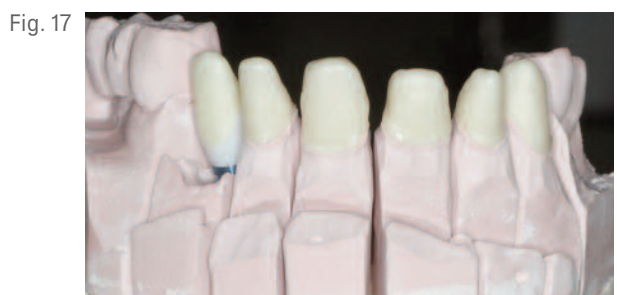

Fig. 17

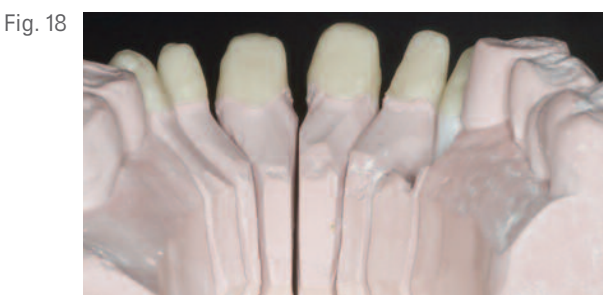

Fig. 18

The maxillary master cast (Fig. 14) and the mandibular diagnostic cast were fabricated and articulated. The maxillary cast was scanned in a 3Shape Scanner, and a Lab Designed Abutment (BIOMET 3i) was designed virtually. The data was sent to the BIOMET 3i PSP Department in Valencia, Spain for fabrication of a Lab Designed Abutment in zirconia. The master cast was then pinned, sectioned, and trimmed (Fig. 15). The implant abutment was scanned (Fig. 16), along with the tooth preparations for fabrication of zirconia copings.

BellaTek™ Zirconia Copings were fabricated in the BIOMET 3i PSP Department and sent to the dental laboratory. These were placed on the master cast (Figs. 17 and 18). ZIROX® Ceramic (Wieland Dental+ Technik GmbH & Co., Pforzheim, Germany) was used

to build the restorations on the copings. Because the material shrinks during firing, the first layer was overcontoured (Fig. 19). After firing, the crowns were placed on the dies in the master cast. A second layer of porcelain was applied (Fig. 20), and the crowns were removed, fired, and replaced onto the dies. A stone was then used to trim the crowns. The crowns were prepared for a final correction firing (Fig. 21). After the final layer of porcelain was applied and fired, the finished crowns were placed back on the master cast (Fig. 22). The patient returned to the dental clinic for delivery of the definitive restorations. The provisional restorations were removed, and the prepared teeth were cleaned with water and 70% alcohol. The Lab Designed Abutment was seated into the internal interface of the implant and secured with a Gold-Tite®

Fig. 19

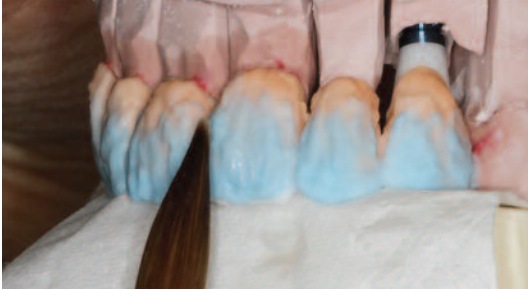

Fig. 20

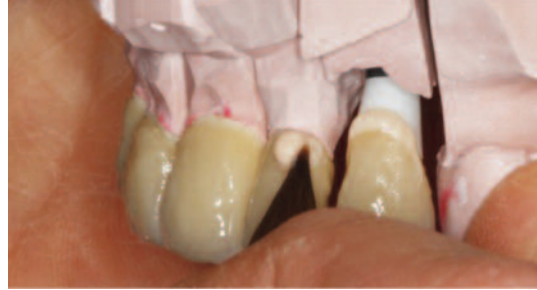

Fig. 21

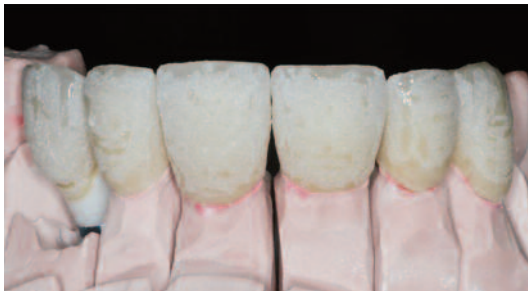

Fig. 22

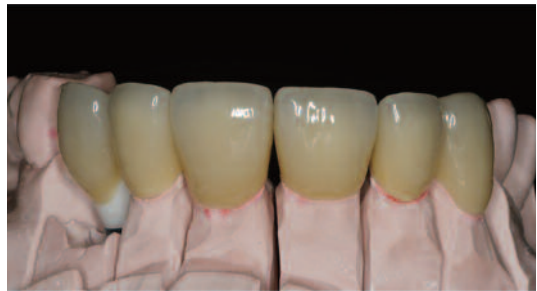

Fig. 23

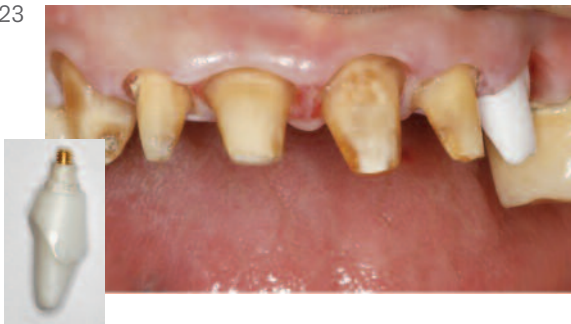
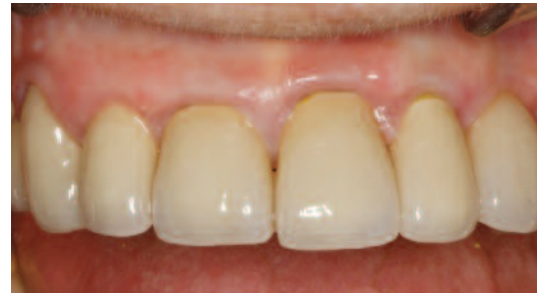
Fig. 24



Abutment Screw tightened to 20Ncm (Fig. 23). The prepared teeth were dried. The crowns were then secured to the implant abutment and the five prepared teeth with RelyX™ Unicem Self-Adhesive Resin Cement (3M ESPE, St. Paul, Minnesota, USA) (Fig. 24). The occlusion was verified, and the excess cement was removed. Periapical radiographs were taken to ensure complete removal of the cement. The patient received oral hygiene instructions and was released.

Clinical Relevance

Current digital technologies include digital scanners, which can be used to create detailed computer models of oral conditions. All-ceramic patient-specific restorative components can then be designed and milled by computer-numerically-controlled milling machines. As a

result, accurate, precise, and aesthetic patient-specific implant-supported and tooth-supported restorations can be delivered to patients.

Laboratory Colleague: Åsa Kärner, Dentalgruvan Dental Laboratory, Falun, Sweden.

**For more information on BellaTek™ and Lab Designed Abutments, please contact your local BIOMET 3i Sales Representative today!*

Pär-Olov Östman, DDS, PhD



Dr. Östman received his dental degree from the University of Umeå, Sweden. He received his PhD degree in the department of Biomaterials, Institute for Surgical Sciences, Sahlgrenska Academy, Gothenberg University, Gothenberg, Sweden. He is head of "Team Holmgatan" private practice clinic in Falun, Sweden and Assistant Professor in the Department of Biomaterials, Institute for Surgical Sciences, Sahlgrenska Academy, Gothenberg University, Gothenberg, Sweden.